

The Lancet · Saturday 4 March 1978

TRANSMISSIBLE AGENT IN NON-A, NON-B HEPATITIS

HARVEY J. ALTER*
PAUL V. HOLLAND*

ROBERT H. PURCELL†
HANS POPPER‡

*Blood Bank Department, Clinical Center, National Institutes of Health, Bethesda, Maryland;

†Laboratory of Infectious Diseases, National Institutes of Health, Bethesda, Maryland; and

‡Stratton Laboratory for Study of Liver Diseases, Mount Sinai School of Medicine of the City University of New York, New York City, N.Y., U.S.A.

Summary Plasma or serum from 4 patients with acute or chronic non-A, non-B post-transfusion hepatitis (P.T.H.) and from a blood-donor implicated in two cases of P.T.H. was inoculated into 5 chimpanzees. Biochemical and histological evidence of hepatitis developed in these 5 chimpanzees but not in a control animal. The mean incubation period in the chimpanzees was 13.4 weeks, compared with 7.7 weeks

in the 4 patients with P.T.H. The peak alanine aminotransferase (A.L.T.) levels in the 5 chimpanzees were 265, 212, 219, 70, and 62 I.U./l. Histological changes ranged from mild to conspicuous hepatitis and generally correlated with the degree of A.L.T. elevation. There was no evidence of clinical disease and all animals went on to biochemical and histological recovery. There was no serological evidence of type A or type B hepatitis. Hepatitis was transmitted by serum derived from patients with chronic as well as acute hepatitis, strongly suggesting a chronic carrier state for the agent responsible for non-A, non-B hepatitis. Non-A, non-B hepatitis thus seems to be due to a transmissible agent which can persist and remain infectious for long periods.

Introduction

INFECTION due to human hepatitis viruses A and B can be identified by assays for various serological and enzymatic markers.¹⁻⁵ At present, 60-90% of post-transfusion hepatitis is serologically unrelated to either of these viral agents.⁶⁻⁹ Neither cytomegalovirus nor the

CLINICAL DATA ON PATIENTS PROVIDING INOCULA ADMINISTERED TO CHIMPANZEES

Subject	Clinical course	Peak A.L.T./A.S.T. (I.U./l)	Peak bilirubin (mg/dl)	Incubation period to first A.L.T. over 100 I.U./l (wk)	Wk after transfusion inoculum obtained* (A.L.T. at that wk)	Volume of inoculum	Chimp receiving inoculum (no.)
1	Acute non-A, non-B P.T.H. progressing to C.A.H.	1600/1400	8.4	8	4 (50) 6 (22) 8 (390) 10 (1000) 11 (520)	4.5 ml serum	165
2	Acute non-A, non-B P.T.H. progressing to C.P.H.	978/256	0.2	10	42 (228)	75 ml plasma	186
3	Acute non-A, non-B P.T.H. Recovered	1506/1400	10.8	6	6 (153) 7 (618) 8 (906)	3 ml serum	189
4	Donor with raised A.L.T. involved in two cases of acute non-A, non-B P.T.H.	474/714	0.2	N.A.	N.A. (474)	75 ml plasma	191
5	Acute non-A, non-B P.T.H. progressing to C.A.H.	468/402	0.8	7	35 (180)	75 ml plasma	196

*When more than one week indicated, 0.5-1 ml samples from each week were pooled and the total volume was given as a single injection.

P.T.H.=post-transfusion hepatitis; C.A.H.=chronic active hepatitis; C.P.H.=chronic persistent hepatitis; N.A.=not applicable;

A.L.T.=alanine aminotransferase (S.G.P.T.); A.S.T.=aspartate aminotransferase (S.G.O.T.).

Epstein-Barr virus has been implicated in such cases,^{6,7} and the existence of at least one additional human hepatitis virus is suspected. No serological marker of this "non-A, non-B" virus has been defined, no viral particle has been observed, and no agent has been isolated in tissue culture. We have investigated the blood of patients with acute or chronic non-A, non-B hepatitis for the presence of an agent transmissible to chimpanzees.

Materials and Methods

Human Inocula

The samples came from subjects identified in a continuing investigation of post-transfusion hepatitis among patients having open heart surgery.⁶ Four were patients; the fifth was a blood-donor (see accompanying table). All the patients had received volunteer-donor blood prescreened for hepatitis-B surface antigen (HB_sAg) by solid-phase radioimmunoassay. Blood-samples were obtained weekly or biweekly during the first three months after transfusion and then monthly for a further three months. Additional samples were obtained when liver enzymes were raised; whenever possible, plasmapheresis was performed on patients with suspected acute or chronic non-A, non-B hepatitis.

Post-transfusion hepatitis was diagnosed when, between 2 and 26 weeks after transfusion, alanine aminotransferase (A.L.T.) rose to 2½ times the upper limit of normal (112 I.U./l) and when a second sample, after at least a week, was over twice the upper limit of normal (90 I.U./l). Icteric hepatitis was diagnosed when the serum-bilirubin exceeded 2.5 mg/dl. Congestive failure, toxic hepatitis, and other causes of raised hepatic enzymes were excluded as far as possible. Diagnosis of non-A, non-B hepatitis was contingent upon the absence of HB_sAg and the absence of antibody seroconversion to HB_sAg, hepatitis B core antigen (HB_cAg), hepatitis A virus (H.A.V.), cytomegalovirus (C.M.V.), and the Epstein-Barr virus (E.B.V.). Liver biopsy specimens were not obtained in the acute phase of the disease, but were obtained when enzyme abnormalities persisted for more than six months.

Subject no. 4 was a blood-donor. Her blood had been given to two patients in whom non-A, non-B hepatitis developed. In the more recent case she was the only donor who proved, on recall, to have raised aminotransferase values. She had no history of previous hepatitis or other medical disease, was not on medication, and denied use of narcotics or heavy intake of alcohol. Her A.L.T. on first recall was 79 I.U./l and it fluctuated between 56 and 474 during the next six months. She complained of nausea and increased fatigue at the time her hepatic enzymes were at their maximum level, but generally she was symptomless. Liver biopsy has not yet been done.

Study in Chimpanzees

Selected samples of plasma or serum from the four patients and from the blood-donor were inoculated intravenously into five chimpanzees in volumes ranging from 3 to 75 ml (see table). The chimpanzees were then monitored weekly for A.L.T., aspartate aminotransferase (A.S.T.), gamma-glutamyl transpeptidase (G.G.T.P.), and HB_sAg. Pre-infusion and six-month post-infusion samples were also tested for antibody to HB_sAg (anti-HB_s), antibody to HB_cAg (anti-HB_c), and antibody to the hepatitis A virus (anti-H.A.V.). When enzyme abnormalities were detected, the animals were plasmapheresed on one or more occasions and serial liver biopsy specimens were obtained.

The chimpanzees were kept at the Laboratory for Experimental Medicine and Surgery in Primates (L.E.M.S.I.P.) in Sterling Forest, New York. Each of the animals had been wild-caught in Sierra Leone, Africa, but had been housed at L.E.M.S.I.P. for at least 2 years when this study was started. At the time of the study, the chimpanzees were between 4 and

5½ years old. Three of them (nos. 165, 186, and 189) had been experimentally infected with the hepatitis-B virus previously and had anti-HB_s and anti-HB_c at the beginning of the study. All were negative for HB_sAg and all had normal hepatic-enzyme levels. Two of the animals (191, 196) had not previously been used in experiments and each was negative for HB_sAg, anti-HB_s, and anti-HB_c. All chimpanzees had anti-H.A.V. at the beginning of the study.

The five chimpanzees were housed in a single room, away from other chimpanzees at L.E.M.S.I.P. A sixth uninoculated control was housed in a separate room. Each chimpanzee was kept in an isolation cage suspended from the wall and separ-

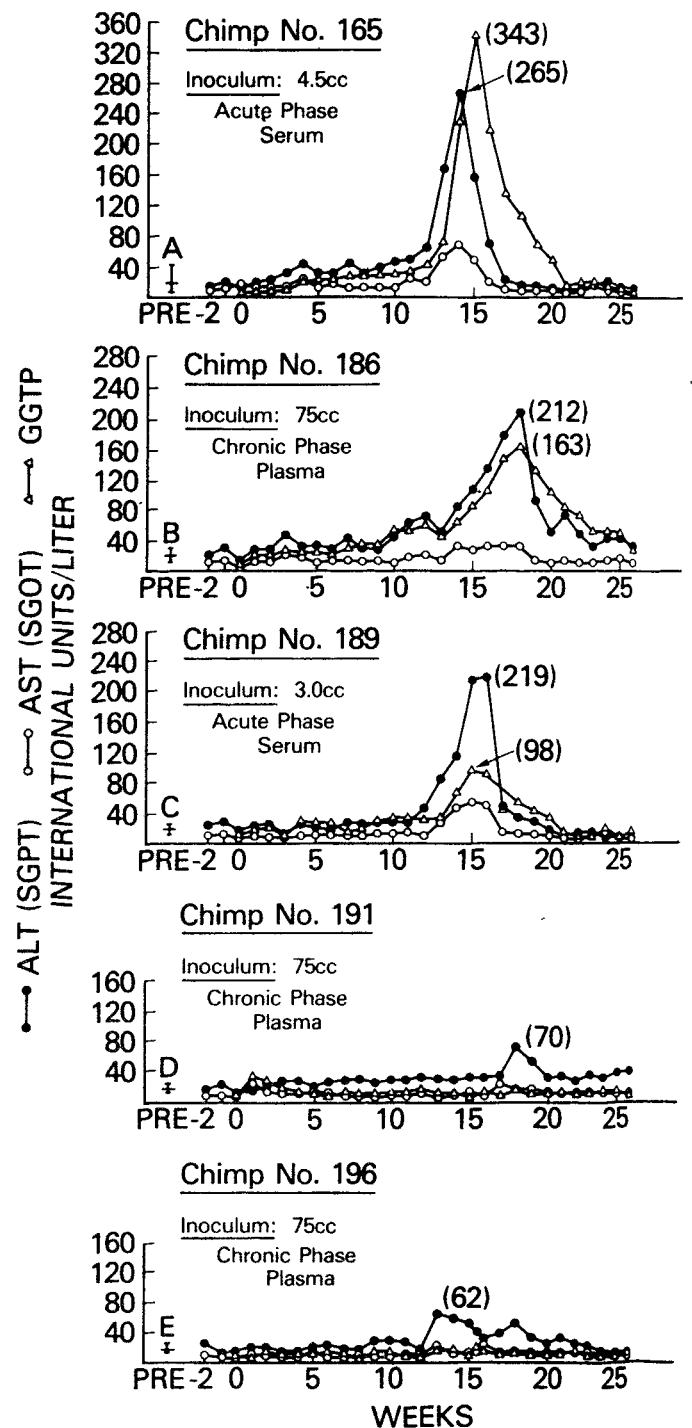


Fig. 1—Serial determinations of alanine aminotransferase, aspartate aminotransferase, and gamma-glutamyl transpeptidase in five chimpanzees inoculated on day 0 with serum or plasma from patients with acute or chronic non-A, non-B hepatitis.

A = mean and range of 18 samples in preceding 6 mo; B = mean and range of 17 samples in preceding 6 mo; C = mean and range of 9 samples in preceding 4 mo; D = mean and range of 13 samples in preceding 6 mo; E = mean and range of 13 samples in preceding 6 mo.

ated from adjacent cages by a 'Plexiglass' barrier. The animals could not touch each other or transfer secretions or excretions from one cage to another. Excreta fell on to plastic mats which were discarded daily. For inoculation, venepuncture, plasmapheresis, or liver biopsy, the animals were anaesthetised in their cage with intravenous ketamine hydrochloride and then transported to an adjacent treatment room which was used only for these animals. There was no contact between animals in the treatment room and all equipment was disposable. Attendants wore gowns, masks, surgical gloves, and surgical shoe covers and were experienced in isolation techniques.

Test Methods

Aminotransferases were measured in chimpanzees by the method of Henry.¹⁰ The range of normal values in juvenile chimpanzees was 6–38 I.U./l for A.L.T. and 6–35 I.U./l for A.S.T. G.G.T.P. was assayed by the method of Szasz,¹¹ with normal values in juvenile chimpanzees ranging between 8 and 24 I.U./l.

HB_sAg and anti-HB_s were tested by solid-phase radioimmunoassay ('Ausria II' and 'Ausab', respectively, Abbott Laboratories). Anti-HB_c was tested by a newly developed solid-phase radioimmunoassay¹² which employs radio-labelled anti-HB_c and is based on competitive inhibition.* A reduction in radioactive counts of more than 50% compared with negative controls was taken as a positive result.

Antibody to hepatitis A antigen was determined by immune adherence haemagglutination assay.¹³ Antibody to C.M.V. was measured by complement fixation;¹⁴ C.M.V. antigen was pre-

*Kindly supplied by Dr Lacy Overby of Abbott Laboratories.




Fig. 2—Biopsy specimen of liver from chimpanzee 165 at the time alanine aminotransferase was 163 I.U./l (week 14).

Hæmatoxylin and eosin, $\times 250$. Note nuclear variation, lobular disarray with "smudging", increased sinusoidal lining cells, acidophilic bodies, focal necrosis, and portal-tract inflammation with some infiltration of parenchyma.

pared from the AD 169 strain of human C.M.V.¹⁵ Paired sera were titrated in duplicate for anti-E.B.V. by immunofluorescence.¹⁶ Liver biopsy specimens were obtained percutaneously with 'Trucut' disposable needles (Travenol). Biopsy specimens were placed in formalin, embedded in paraffin, sectioned, stained with hæmatoxylin and eosin, and read under code by H. P.

Results

Chimp 165 had had 18 blood-samples taken in the six months before inoculation with 4.5 ml of acute-phase serum from subject 1. In only one sample did the A.L.T. exceed 25 I.U./l (value of 42) and the A.S.T. was never higher than 27 I.U./l. A mild rise in A.L.T. began three weeks after inoculation and persisted through week 11 (fig. 1). G.G.T.P. followed a similar pattern but did not rise until week five. There were no significant changes in A.S.T. during this early period. A.L.T. began a steep rise during week twelve, peaked at 265 I.U./l during week fourteen and returned to normal by week seventeen. G.G.T.P. followed a similar, but slightly delayed pattern, reaching a peak of 343 I.U./l during week fifteen and returning to normal by week twenty-one. A.S.T. paralleled A.L.T. and G.G.T.P., but the magnitude of change was considerably less. The animal remained HB_sAg negative throughout this time and was positive for anti-HB_s, anti-HB_c, and anti-H.A.V. before the study began. Liver biopsy specimens obtained at the time of peak increases in hepatic enzymes (weeks thirteen and fourteen) showed a moderately severe acute hepatitis (fig. 2). There was variation in the size and staining quality of hepatocyte nuclei and the cytoplasm was irregularly clumped. Some hepatocytes were replaced by inflammatory cells (focal necrosis) and there were moderate numbers of acidophilic bodies. There was a distinct increase in sinusoidal lining cells. The portal tracts were densely infiltrated by mononuclear cells. In general, the border between portal tracts and the surrounding parenchyma was sharp, but in places the limiting plate was eroded and cellular exudate spilled into the parenchyma. Two months later (week twenty-two), when A.L.T., A.S.T., and G.G.T.P. were normal, the liver was histologically normal.

Chimp 186 had had 17 blood-samples taken in the six months before the beginning of this study; the highest A.L.T. was 25 I.U./l and the highest A.S.T. 20 I.U./l. As seen in fig. 1, there was a slight and fluctuant increase of A.L.T. beginning three weeks after the animal received 75 ml of chronic-phase plasma from subject 2. Definite increases of hepatic enzymes did not appear until weeks ten to eleven. The animal remained HB_sAg negative throughout and was positive for anti-HB_s, anti-HB_c, and anti-H.A.V. when the study began. Liver biopsy specimens obtained during weeks thirteen and fourteen showed an acute hepatitis which was histologically similar to that seen in chimpanzee 165, but less conspicuous. Subsequent biopsies (weeks sixteen and eighteen) showed considerable improvement, but a specimen taken during week twenty-two showed increased portal-tract inflammation and focal necrosis, despite improving values for A.L.T. and G.G.T.P.

Chimp 189 had 9 blood-samples taken in the four months before it received 3 ml of acute-phase serum from subject 3. The highest A.L.T. during this time was 27 and the highest A.S.T. was 20. Unlike chimps 165 and

186, this animal did not show an elevation in A.L.T. and G.G.T.P. three to four weeks after inoculation. There was, however, a definite rise in A.L.T., beginning at week 12 (fig. 1). G.G.T.P. and A.S.T. followed a similar pattern, but the increases were considerably smaller. HB_sAg was not detected and anti-HB_s, anti-HB_c, and anti-H.A.V. were already present when the study began. Histologically the liver was very similar to that of chimp 186, showing an acute hepatitis with acidophilic bodies, focal necrosis, and a conspicuous portal-tract inflammatory reaction. Subsequent biopsy specimens showed striking improvement.

Chimp 191 had had 13 blood-samples taken in the 6 months before receiving 75 ml of plasma from subject 4 (the blood-donor). The highest A.L.T. during this time was 22 I.U./l and the highest A.S.T., 20 I.U./l. The enzymatic response was not great and was later than that in the other animals (fig. 1). Neither A.S.T. nor G.G.T.P. became abnormal. HB_sAg, anti-HB_s, and anti-HB_c were not detected. Liver biopsy showed only borderline changes including activation of sinusoidal lining cells, a few areas of focal necrosis, and a minimal portal inflammatory reaction.

In 13 blood-samples from *chimp 196* in the six months before inoculation the highest A.L.T. was 25 I.U./l and the highest A.S.T. 20 I.U./l. The enzyme response to transfusion with 75 ml of chronic-phase plasma from subject 5 was also small, but it was definite and the temporal relation to transfusion was very similar to that in chimps 165, 186, and 189 (fig. 1). A.L.T. reached a maximum at week thirteen and there was a secondary rise during week eighteen. There was no concomitant rise in A.S.T. or G.G.T.P. In this animal HB_sAg, anti-HB_s, and anti-HB_c were never detected. Liver biopsy during week eighteen revealed a mild diffuse hepatitis; although the enzyme abnormalities were much less than in chimp 186, the histological lesions were very similar. Partial resolution had occurred by week twenty-two.

Chimp 183 was an uninoculated control. During the twenty-six week follow-up the highest A.L.T., A.S.T., and G.G.T.P. were 20, 19, and 22 I.U./l. HB_sAg was not detectable. Anti-HB_s, anti-HB_c, and anti-H.A.V. were present before the study began. Neither the uninoculated control nor any of the inoculated animals became clinically ill.

Discussion

Indirect evidence that an infectious agent is responsible for non-A, non-B hepatitis has been threefold: (1) a variable, but defined incubation period intermediate between that of type A and type B hepatitis (generally six to twelve weeks); (2) hepatic histology which by hæmatoxylin and eosin stain is virtually indistinguishable from that of type A or type B viral hepatitis; and (3) a positive correlation between the development of non-A, non-B hepatitis and the source of donor blood—like type B hepatitis, non-A, non-B hepatitis is about ten times more common after receipt of paid-donor blood than after receipt of volunteer-donor blood.⁷

We chose the chimpanzee as an indicator of a transmissible infectious agent because this animal is susceptible to both hepatitis A and hepatitis B virus infection. Several previous attempts to transmit non-A, non-B hepatitis to chimpanzees have been unsuccessful,¹⁷ but

whether the inoculum was non-infectious or the particular chimpanzees were immune could not be ascertained. Lately, Hollinger et al.¹⁸ have recorded modest increases in A.L.T. (maximum 75 I.U./l) in 4 of 5 chimpanzees inoculated with material either from donors implicated in a case of non-A, non-B hepatitis or from recipients with non-A, non-B post-transfusion hepatitis. Minimal histological changes, primarily Kupffer-cell hyperplasia and swelling of hepatocytes, were noted in relation to A.L.T. elevations, but were not absolutely diagnostic of hepatitis.

In the study described here, chimps 165, 196, and 189 showed unequivocal enzymatic and histological evidence of hepatitis. In chimps 191 and 196 the diagnosis of hepatitis was less certain; however, the A.L.T. reached distinctly higher levels after inoculation than in the baseline period, and higher, too, than those in the uninoculated control chimpanzee. In addition, enzyme abnormalities persisted for at least two weeks and the A.L.T. reached a peak at a post-inoculation interval similar to that in the three chimpanzees with unequivocal hepatitis. Lastly, in chimp 196, although enzyme abnormalities were minor, biopsy showed definite hepatitis.

There were several additional observations of interest. First, the incubation period in the chimpanzees, as judged by the first A.L.T. over 50 I.U./l, was somewhat longer than that in the human beings from whom the inocula came (13.4 weeks in the chimpanzees compared with 7.7 weeks in the four patients with post-transfusion hepatitis), though in one patient/chimp pair the incubation periods were almost identical.

Second, the three chimpanzees with the greatest enzyme rises were the ones that had been previously infected with type B hepatitis. We do not feel that this represents recrudescence of the type B infection since each had had repeatedly normal enzymes for at least four months before entry into this study and because each was persistently HB_sAg negative. In addition, before the present study was started, each chimpanzee had acquired anti-HB_c and anti-HB_s—which generally denote complete recovery from type B virus infection. It is more plausible that these three animals received a more virulent inoculum or that their host response was such as to induce more severe hepatic destruction. Such variability of host response has been clearly demonstrated in type B viral infections of both man¹⁹ and chimpanzees.²⁰ Diverse human responses to identical non-A, non-B inocula have also been demonstrated in a retrospective, serological analysis of volunteer studies performed in the early 1950s.²¹

Third, non-A, non-B hepatitis was transmitted by serum or plasma obtained either in the acute or in the chronic phase of the disease. This provides good evidence for a chronic carrier state. Only the existence of such a carrier state can account for the large number of non-A, non-B hepatitis cases which derive from seemingly healthy donors. Indeed, this is a key observation in this study.

Fourth, the histological lesion in these chimpanzees was identical to that seen in type B hepatitis, in that the whole lobule was involved, and in that streaks of focal necrosis extended into the central zone. In contrast, the changes seen in hepatitis A are primarily periportal. These histological differences may account for the tendency of type B and non-A, non-B hepatitis to progress

to chronic liver disease whereas type A hepatitis seems to be a self-limited acute disease.²²

Fifth, we employed three tests of hepatocellular dysfunction, of which A.L.T. was the most consistent: it was the only enzyme raised in all five chimpanzees, and in four of them was the one showing greatest abnormality. G.G.T.P. had a very similar pattern to that of A.L.T. and in one chimpanzee reached a higher and more sustained level. However, in the two chimpanzees with the mildest A.L.T. increases, the G.G.T.P. remained normal. A.S.T. was the least reliable of the tests.

Lastly, the volume of inoculum did not seem to influence the severity of the ensuing disease; two of the three chimpanzees with severe disease had received less than 4 ml of infectious material, whereas the two with the mildest hepatitis received 75 ml. In future experiments, therefore, smaller inocula can be used. Similarly, the stage of human non-A, non-B hepatitis at which the blood was obtained did not seem to influence the disease course: one animal which received chronic-phase plasma had a response almost identical to those of the two animals receiving acute-phase serum.

We have shown that blood from human beings with apparent non-A, non-B hepatitis contains an agent capable of causing similar disease in chimpanzees. This animal model may now permit more definitive characterisation of non-A, non-B inocula, including infectivity titres; assessment of cross immunity to determine whether non-A, non-B hepatitis exists in more than one variety; detection of virus material in liver; and the use of such material in development of a serological test for non-A, non-B hepatitis.

We thank Delores Koziol, Max Shapiro, Dana James, and Lenita Hudson for expert technical assistance.

Requests for reprints should be addressed to H. J. A., National Institutes of Health Clinical Center, Blood Bank Department, Bethesda, Maryland 20014, U.S.A.

REFERENCES

1. Prince, A. M. *Proc. natn. Acad. Sci. U.S.A.* 1968, **60**, 814.
2. Almeida, J. J., Rubenstein, D., Stott, E. J. *Lancet*, 1971, **ii**, 1225.
3. Lander, J. J., Alter, H. J., Purcell, R. H. *J. Immun.* 1971, **106**, 1166.
4. Feinstone, S. M., Kapikian, A. Z., Purcell, R. H. *Science*, 1973, **182**, 1026.
5. Kaplan, P. M., Greenman, R. L., Gerin, J. L., Purcell, R. H., Robinson, W. S. *J. Virol.* 1973, **12**, 995.
6. Alter, H. J., Purcell, R. H., Holland, P. V., Feinstone, J. M., Morrow, A. G., Moritsugu, Y. *Lancet*, 1975, **ii**, 1.
7. Prince, A. M., Brotman, B., Grady, G. F., Kuhns, W. J., Hazz, C., Leoine, R. W., Millian, S. J. *ibid.* 1974, **ii**, 241.
8. Hollinger, F. B., Aach, R. D., Gitnick, G. F., Roche, J. K., Melnick, J. L. *New Engl. J. Med.* 1973, **289**, 385.
9. Seëff, L. B., Zimmerman, H. J., Wright, E. C., McCollum, R. W. *Am. J. med. Sci.* 1975, **270**, 355.
10. Henry, R. J. *Am. J. clin. Path.* 1960, **34**, 381.
11. Szasz, G. *Clin. Chem.* 1969, **15**, 124.
12. Overby, L. R., Ling, C. M. *Rush-Presbyterian-St. Luke's med. Bull.* 1976, **15**, 83.
13. Miller, W. J., Provost, P. J., McAleer, W. J., Ittenson, O. L., Villarejos, V. W., Hilleman, M. *Proc. Soc. exp. Biol. Med.* 1975, **149**, 254.
14. Purcell, R. H., Walsh, J. H., Holland, P. V., Morrow, A. G., Wood, S., Chanock, R. M. *J. infect. Dis.* 1971, **123**, 406.
15. Rowe, W. P., Hartley, J. W., Waterman, S., Turner, H. C., Huebner, R. J. *Proc. Soc. exp. Biol. Med.* 1956, **92**, 418.
16. Henle, G., Henle, W. *J. Bact.* 1966, **91**, 1248.
17. Purcell, R. H., Barker, L. F. Personal communication.
18. Hollinger, F. B., Aach, R. D., Lander, J., Gitnick, G. L., Szmuness, W., Stevens, C., Mosley, J. W., Peters, R., Weiner, J., Personal communication.
19. Barker, L. F., Murray, R. *Am. J. med. Sci.* 1972, **263**, 27.
20. Barker, L. F., Maynard, J. C., Purcell, R. H., Hoofnagle, J. H., Berquist, K. R., London, W. T., Gerety, R. J., Krushak, D. H. *J. infect. Dis.* 1975, **132**, 451.
21. Hoofnagle, J. H., Gerety, R. J., Tabor, E., Feinstone, S. M., Barker, L. F., Purcell, R. H. *Ann. intern. Med.* 1977, **87**, 14.
22. Dienstag, J. L., Popper, H., Purcell, R. H. *Am. J. Path.* 1976, **85**, 131.

TRANSMISSION OF NON-A, NON-B HEPATITIS FROM MAN TO CHIMPANZEE

EDWARD TABOR
JACQUES A. DRUCKER
JAY H. HOOFNAGLE
MILTON APRIL
GERONIMA PINEDA-TAMONDONG

ROBERT J. GERETY
LEONARD B. SEEFF
DANIEL R. JACKSON
LEWELLYS F. BARKER

Division of Blood and Blood Products and Division of Pathology, Bureau of Biologics, Food and Drug Administration, Bethesda, Maryland;
Department of Medicine, Veterans Administration Hospital, Washington, D.C.;
Georgetown University School of Medicine, Washington, D.C.;
and American National Red Cross, Washington, D.C., U.S.A.

Summary Non-A, non-B hepatitis was transmitted to four colony-born chimpanzees by intravenous inoculation of human sera. Two chimpanzees were inoculated with serum from a patient with a clinical and serological diagnosis of chronic non-A, non-B hepatitis whose blood appeared to transmit this disease to a nurse following accidental needle-stick, and the other two chimpanzees were inoculated with serum from either of two former blood-donors whose HB_sAg-negative blood appeared to transmit clinically recognisable hepatitis, and who were found to have raised serum-aminotransferase levels 1½ and 5 years later. Serum-aminotransferase levels rose in all four chimpanzees, beginning 2–4 weeks after inoculation: peak alanine-aminotransferase values were 210 to 328 I.U./l. Evidence of hepatitis was present in liver biopsy specimens from all four chimpanzees, beginning 8–10 weeks after inoculation. None showed serological evidence of infection with hepatitis A virus, hepatitis B virus, cytomegalovirus, or Epstein-Barr virus.

Introduction

SINCE the discovery of hepatitis B surface antigen (HB_sAg)¹ and hepatitis A virus (H.A.V.),² hepatitis types A and B have become distinguishable by specific serological tests. A further type of hepatitis, in which no agent has yet been identified, has been designated "non-A, non-B hepatitis".^{3,4} Non-A, non-B hepatitis represents a high proportion of the cases of post-transfusion hepatitis in the United States, now that HB_sAg-positive donor blood is excluded.^{4,5} The association of a transmissible agent with this disease has been suggested by investigation of stored serum specimens taken in studies of volunteers in the 1950s.⁶ However, investigation of the disease has been hampered by the lack of a serum marker and of an animal model. We have tried to demonstrate a transmissible agent by inoculating human sera into young chimpanzees born in captivity.

Methods

Inocula

Inoculum I was obtained from a patient with aplastic anaemia at the Veterans Administration Hospital, Washington, D.C. Hepatitis developed after transfusion and aminotransferase levels remained high for more than 4 years. 6 weeks after the onset of his disease, a nurse caring for him injured herself with a broken capillary pipette contaminated with his blood.